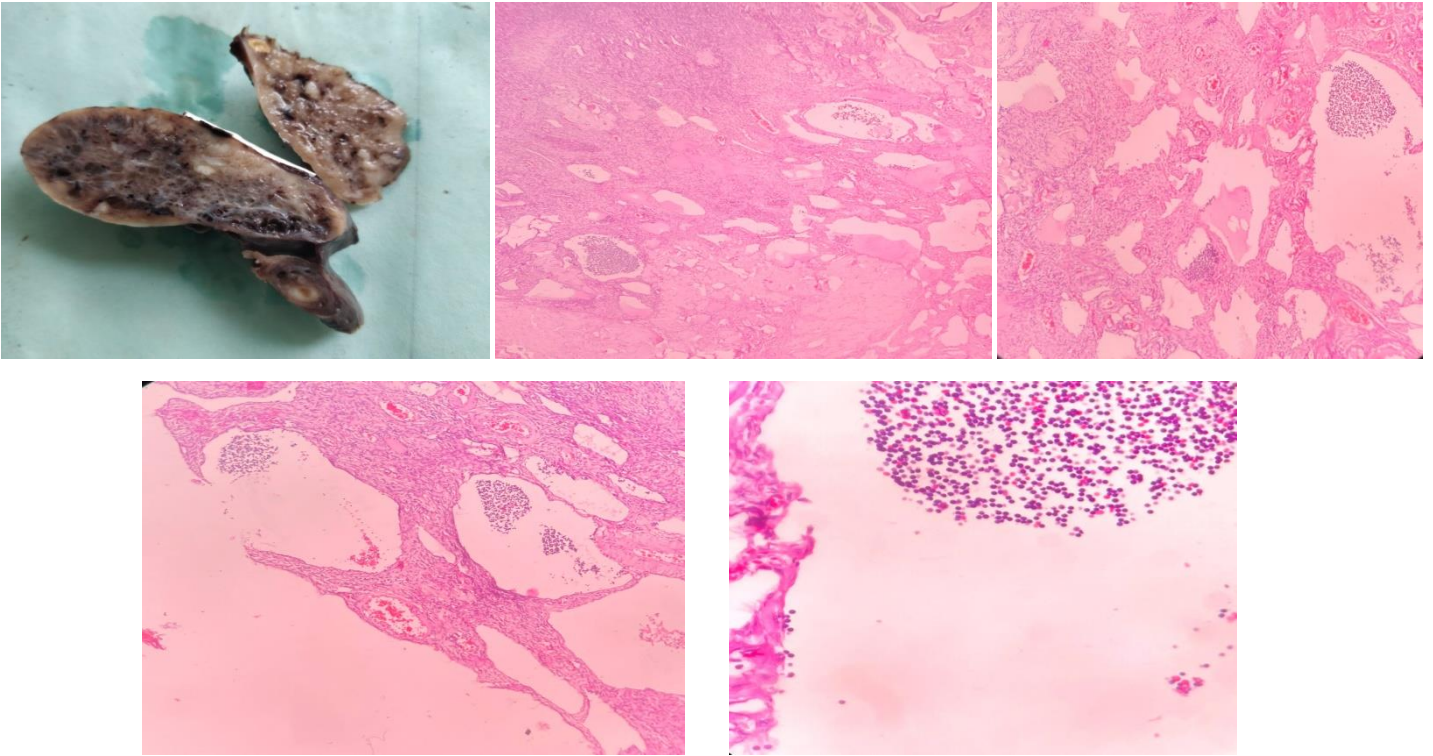


CASE OF THE WEEK – 25.02.2023

OVARIAN LYMPHANGIOMA

History:

- 45 yrs / female
- Bilateral ovarian masses
- Measuring 5 cm each
- Cut section – multiple cystic spaces filled with hemorrhagic fluid



Microscopy:

Sections studied show ovarian parenchyma along with multiple, dilated lymphatic channels lined by flattened endothelium. Lumen of the channels is filled with proteinaceous fluid and lymphocytes. The wall of the lymphatic channels is showing lymphocytic infiltration.

Impression: Ovarian lymphangioma.