

CASE OF THE WEEK – 11.02.2023

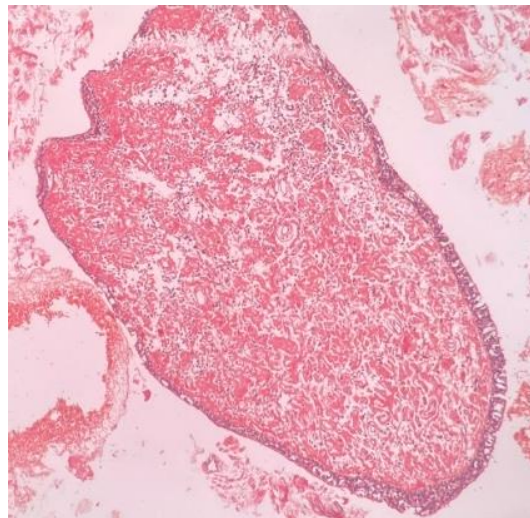
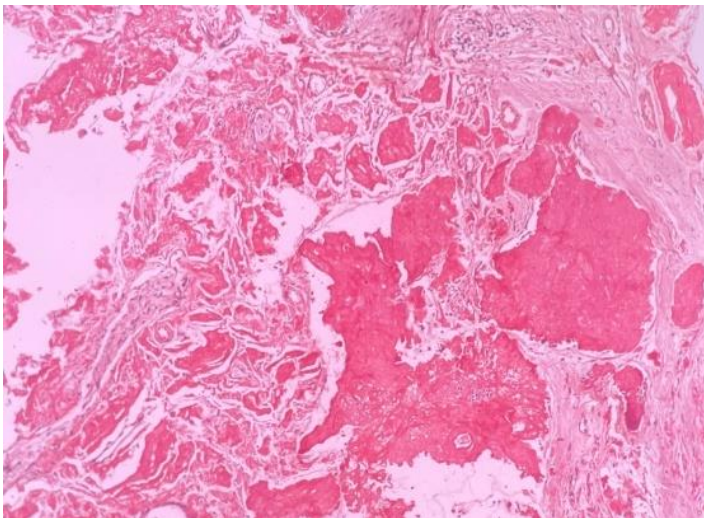
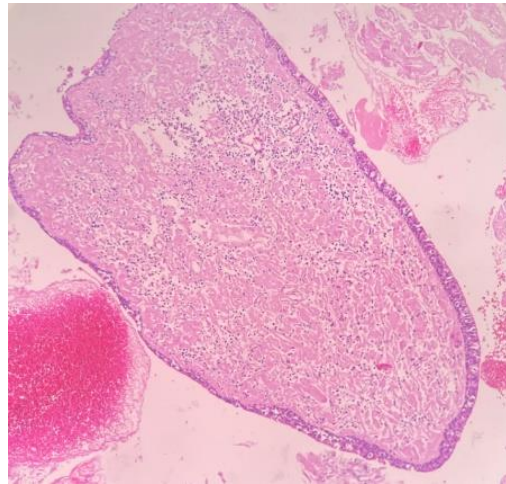
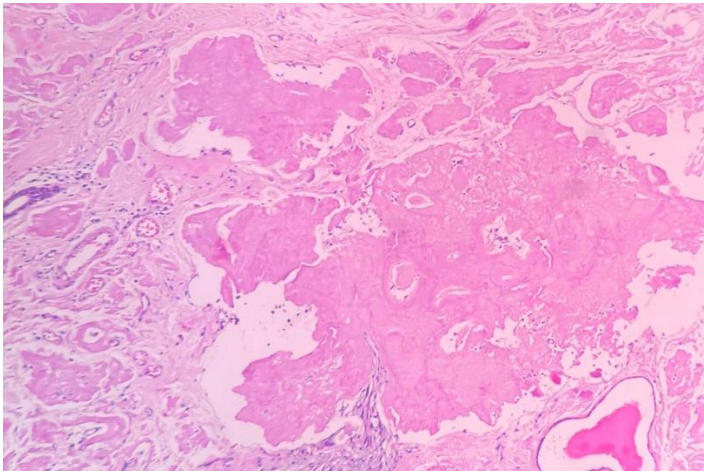
Laryngeal Amyloidosis

History:

37 year female came with complaints of change of voice since 3 years. Laryngoscopy showed swelling in the supraglottic region extending to anterior commissure.

Histopathology:

Microscopic examination showed polypoid lesion lined by respiratory mucosa with focal squamous metaplasia. Stroma shows dense acellular amorphous eosinophilic deposits accentuated around blood vessels and seromucinous glands. Focal lymphoplasmacytic infiltration noted.



Congo Red special stain – Strongly positive.
No neoplastic pathology

Impression: Laryngeal Amyloidosis.