

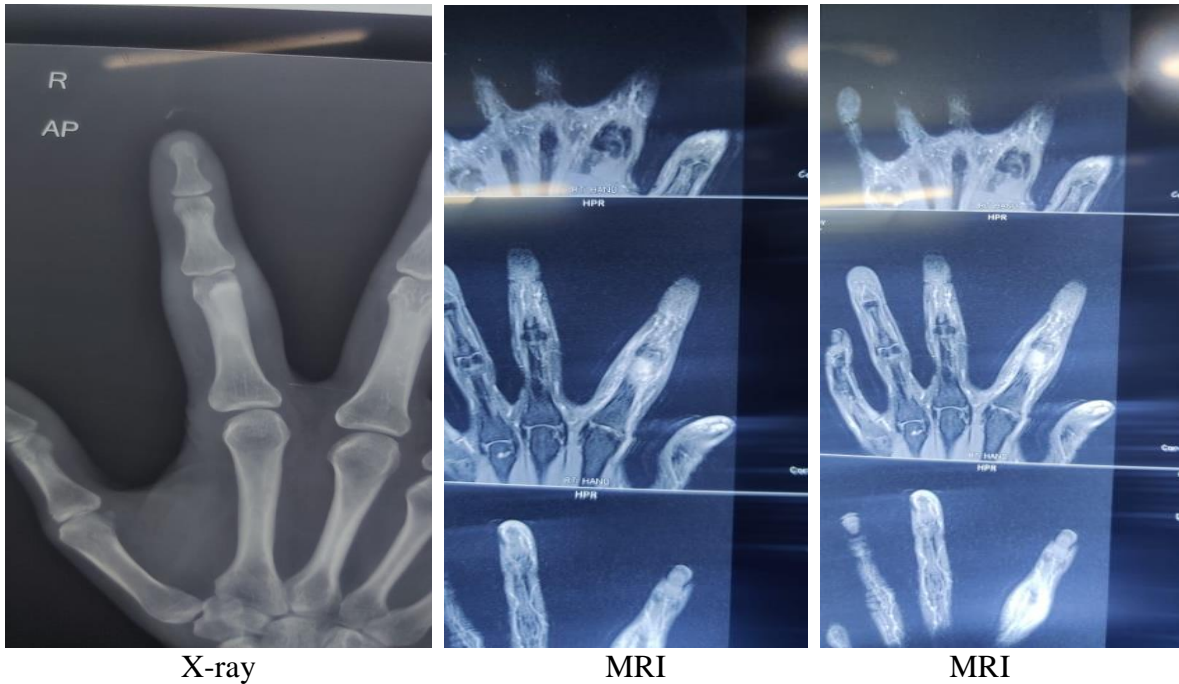
## CASE OF THE WEEK – 11.03.2023

### MELORHOSTEOSIS

#### History:

A 30 year old male came with complaints of swelling in Right index finger.

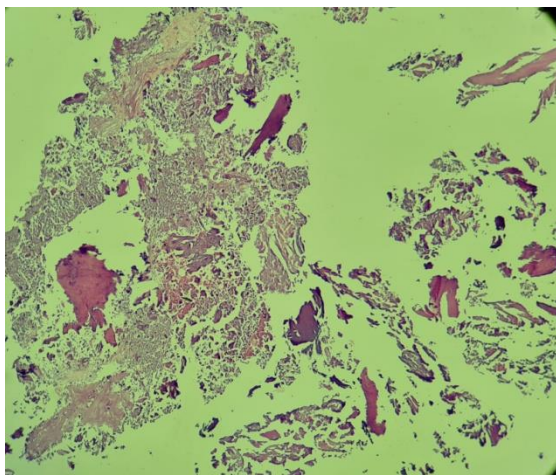
**MRI** – Well defined sclerosed lesion in proximal phalanx of right index finger.  
– Most likely melorhostosis.



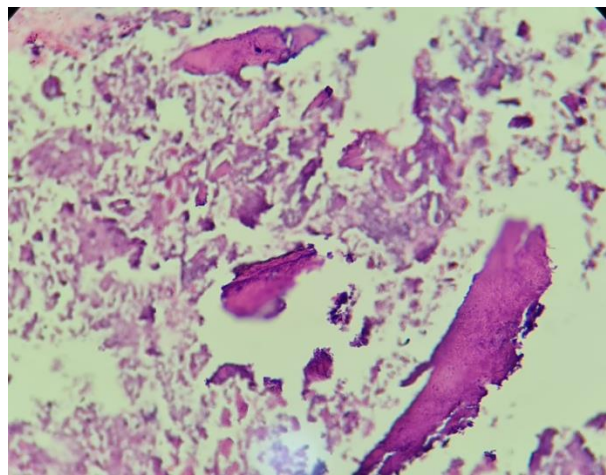
X-ray

MRI

MRI



4X



40X

**Nature of Specimen:** Biopsy taken from Intramedullary lesion of right index finger proximal phalanx.

**Gross:** Received multiple tiny firm bits altogether measuring 8x5x3 mms.

**Microscopy:** Sections reveal admixture of mature lamellar bone and immature woven bone.

**Impression:** Histo-morphological features in correlation with radiological findings suggest the possibility of Melorheostosis.