

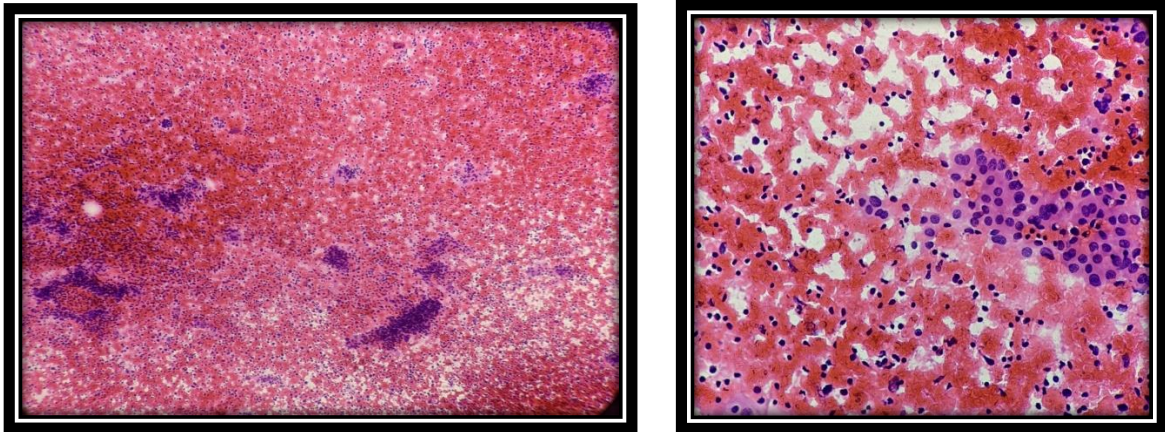
Case of the week 01.04.2023

Primary Thyroid Lymphoma

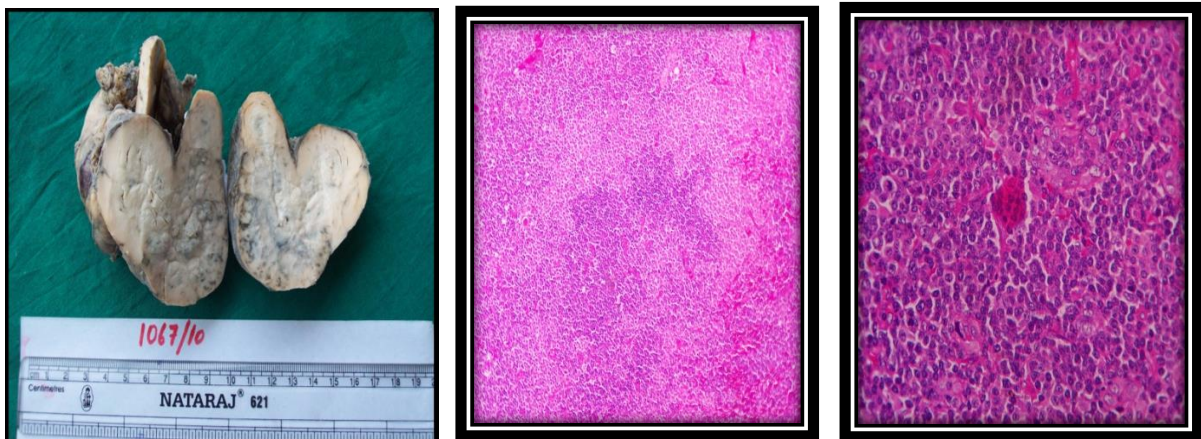
Clinical history - A 16 year old girl came with complaints of pain and swelling in thyroid region since 3 years. Swelling is rapidly increasing in size since 3 months. Difficulty in deglutition is present

Ultrasound of thyroid - revealed large $5.1 \times 3.1 \times 2.5$ cm hypoechoic mass occupying almost the entire thyroid gland

FNAC of thyroid swelling – features are suggestive of lymphocytic thyroiditis



Gross – Received total thyroidectomy specimen measuring 8x6x4cm



Microscopy – Diffuse architectural effacement of thyroid parenchyma with proliferation of atypical lymphoid cells, which are aggregates at some places. Remanent colloid filled thyroid follicles are noted in between. Areas of intraluminal lymphocytes so called MALT balls are noted.

Immunohistochemistry – CD 20 – positive , BCL-6 – Negative, CD 10 – negative, cytokeratin – positive

Impression – Primary Thyroid Lymphoma – Extranodal Marginal Zone Lymphoma